

## HISTOPATHOLOGICAL EFFECT OF AZATHIOPRINE ON LIVER, INTESTINE AND SPLEEN OF ALBINO MICE

Dina Khudhair Hussein Ali\*

Department of Biology, College of Science, Baghdad University, Baghdad, Iraq  
E. mail: \*dinakhudhair4@gmail.com.

Article received 01.11.2017, Revised 10.12.2018, Accepted 18.12.2018

### ABSTRACT

This study was carried out to study the effect of azathioprine drug on some histological structure in albino mice. sixty adult female albino mice (20mice/group), were used in this study, the average body weights are 30-32 gm. two doses of azathioprine (50 mg/kg/b wt. and 100 mg/kg/b wt.) were given by the oral route daily for 40 days to the second and third group respectively, while control group was given normal saline. The histopathological examination of the treated animal for liver showed congestion with dilation of portal vein, Dilation of sinusoids and Mono-nuclear cell aggregation for the second group while for the third treated group showed small granulomatous lesion of mononuclear cells, Enlargement and proliferation of kupper cells, Severe necrosis. Sever vacuolar degeneration of hepatocytes. The histopathological section of spleen was showed Infiltration of megakaryocyte for the second group while for the third group showed hypertrophy of central arteriole with dilation and infiltration of mono-nuclear cell mainly macrophage and plasma cell in red pulp. The histological changes in intestine tissue of the treated animals showed vacular degeneration of epithelial cell with hyperplasia of goblet cell which produce allots of mucin for the second group while for the third group showed infiltration of mononuclear cells between glands. From this study we concluded that there was harmful effect of azathioprine on different tissues of the experimental animal dependent on increasing dose of this drug.

Keywords: azathioprine, spleen, mice, Histology, liver, harmful, spleen

### INTRODUCTION

Azathioprine (Imuran) belongs to the chemical class of purine homologues, it is an imidazole transformed to 6- thioionsinic acid and 6-mercaptourine in body [Day *et al.*, 2005]. in organ transplantation. It is act to prevent rejection of organs as an immunosuppressive drug and auto-immune diseases. It is used also to treat some medical diseases like Crohn's disease and rheumatoid arthritis [Patel and McCall, 2006] to treat an array of auto-immune diseases like dermatitis and restrictive lung disease with prevent rejection of transplanted organs thus Azathioprine is used alone or with other immunosuppressive drug. It is also important for inflammatory bowel disease [Evans, 2004]. since it stop the action of amido-phosphoribosyl transferase enzyme, So it block the synthesis of RNA and DNA by cells [Sami, 2016]. In spite of that its mediated the action of Thioguanosine triphosphate (TGTP) which is incurporated in to RNA synthesis [Maltzman and Koretzky, 2003]. The mode of action to azathioprine is send activated mononuclear cells and T cells into apoptosis (programmed cell death) by interacts with the GTP-binding protein, stopping the regulation of specific protein Bcl-xL [Steinhilber, *et al.*, 2005] when the persons begins to use this drug, they have common side effects including Nausea, dizziness, vomiting, skin rashes, fatigue and diarrhea. Win transplant patients receiving this drug hair loss is usually

seen. One of side effect of azathioprine is suppresses the bone marrow synthesis so patients can develop anemia. Acute pancreatitis can occur in patients with Crohn's disease [Weersma, *et al.*, 2004].

### MATERIALS AND METHODS

**ANIMAL BREEDING:** Forty adults, 15-16 weeks old, female albino mice (*Mus musculus*), weighing 30-32gm were obtained from animal's house of the College of Science, University of Baghdad, Iraq. The animals were kept in a well-ventilated room, in standard plastic cages at 24-28°C temperature with 12 hrs natural light and 12 hrs darkness. The mice had free access to tap water and dry pellets which obtained from local market *ad libitum*. The mice were allowed to acclimatize for few days.

**TREATMENT:** Animals where divided into 3 groups, 20 per group as follows:

**Group 1:** animals were treated with normal saline.

**Group 2** animal were treated with 50mg/ kg body weight of azathioprine.

**Group 3:** animals were treated with 100 mg/kg/ body weight of azathioprine.

Azathioprine given daily by the oral route with 0.1ml of 50mg/kg body weight and 100mg/kg body weight of azathioprine respectively by using gavage tube.

**ANIMALS KILLING AND SPECIMENS COLLECTION:** By cervical dislocation [Siddique, *et al.*, 2015], all mice were killed after 40 days. Liver, spleen and intestine were removed and fixed in Bouin's fluid for 12-24 hours then washed several times with ethanol 70% by dehydrated process and embedded in paraffin and kept until use. Serial sections were cutted of 5 microns thickness using a rotatory microtome and then stained with hematoxylin and eosin (H&E) then examined using light microscope. Photographs were taken by digital camera [Bancroft and Stevens, 1982].

## RESULT AND DISCUSSION

Azathioprine is an immune suppressive drug, it is the most important drug used in the therapy of rheumatoid arthritis; inflammatory bowel disease; acute lymphoblastic and leukemia. The histological examination of liver, spleen and intestine in control group shows normal histology as show in Fig 1, 4 and 8. The histopathological examination of liver for treated animals with 50 mg/kg body weight (second group) of azathioprine showed dilation of portal vein with congestion, mononuclear cell aggregation (MNC) and dilation of sinusoids Fig 2 ,while for the third group which treated with 100mg/kg body weight showed small granulomatous lesion of mononuclear cells, Enlargement and proliferation of kupper cells, severe necrosis. sever vacuolar degeneration of hepatocytes Fig 3.

The histopathological section of spleen was showed Infiltration of megakaryocyte for the second group which treated with 50 mg/kg body weight while for the third group which treated with 100 mg/kg body weight showed hypertrophy of central arteriole with dilation and infiltration of mononuclear cell (MNC) mainly macrophage and plasma cell in red pulp Fig 5, 6 and 7.

Histological changes in of tissue of intestine for the second treated animals with 50 mg/kg body weight showed vascular degeneration of epithelial cell with hyperplasia of goblet cell witch produce allots of mucin while for the third group which treated with 100 mg/kg body weight showed infiltration of mononuclear cells between glands Fig 9 and 10.

The harmful effect of azathioprine on the infected tissues may be due to azathioprine toxicity, Functional polymorphisms of several enzymes involved in the metabolism of thiopurines like azathioprine have been linked with toxicity [Schmaier, 2008]. Mion *et al.*, 1991] demonstrated that azathioprine induces hepatotoxicity, since it causes lesions in the liver, hyperplasia and peri sinusoidal

fibrosis in it and this agree with our study (Fig 2, 3) [César *et al.*, 2004]. The production free radical in organs and tissues are the cause of toxic effects of azathioprine since its reduce to stop the synthesis of different specialized cell like hepatocytes by selective inhibiting the synthesis of adenine which belong to purine nucleotides and this agree with our study Fig 3 [Weersma *et al.*, 2004].

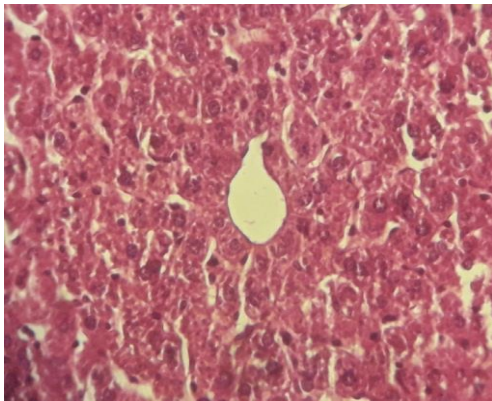
Azathioprine cause acute pancreatitis, so it has harmful effect on liver cell which is responsible for detoxification [Machalinska *et al.*, 2002] And kuffer cell in liver play role in detoxification also [Niels *et al.*, 2016, Hascheck and Rausseaux, 1998]. The severity of these negative effects of azathioprine on animal organs may be related to the duration of exposure [Maltzman and Koretzky, 2003].

No study available reported the effect of azathioprine on the tissue of spleen and intestine, but the results of histological examination in this study may support the negative effect of azathioprine on these tissues. The harmful effect of azathioprine on tissue of spleen and intestine especially vascular degeneration may be due to Azathioprine inhibits the regeneration of cells by interrupting with DNA synthesis [Dearden and Nicholson, 1984] as in Fig 7 & 9, Since azathioprine belongs to NSAIDs, there is direct relation-ship between formation of gastric ulcer and anti-inflammatory of NSAIDs [Bjarnason *et al.*, 1987]. The clinical implications in some patient receiving NSAIDs drugs may bleed from the small intestine and lose protein, contributing to iron deficiency and hypoalbuminaemia [Gately and Li, 2004] and this agree with our study. NSAIDs also induce apoptosis, cell growth inhibition and antiangiogenesis such as azathioprine [Patel, *et al.*, 2006].

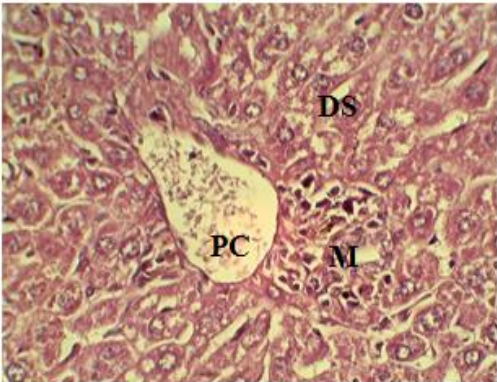
After patients take azathioprine, the absorption completely occurred in digestive tract very quickly [Jewell and Truelove, 1972]. Jewell and Truelove [1972] demonstrated that azathioprine cause gastrointestinal disturbance, the azathioprine treated patients suffered from relapses of the ulcerative colitis (reoccurrence of symptoms which include diarrhea and inflammation in this state) [Casey, 1968].

Animal experiments suggest that immune-suppressive therapy associated with a long-term risk of neoplasia [Geary and Barclay, 2005]. In 6-mercaptopurine (6-MP) like azathioprine treated patients and due to complex metabolism and genetic polymorphism transforming enzymes, there is a wide inter and intra variation in concentration of toxic metabolites, So, this may reflect the harmful effect of azathioprine on the infected tissue as shown in Fig. 5 and 6 [Pytrus *et al.*, 2013]. In chi-

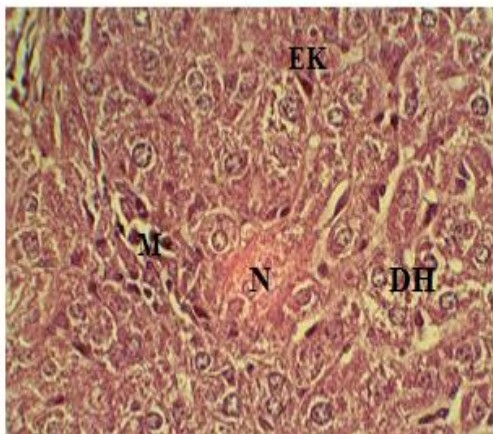
liver treated with immunosuppressive drugs (azathioprine), anemia was diagnosed due to changes in the upper gastrointestinal tract, the location of the ileum, intestinal villous atrophy. And this study was agreed with our result Fig 10.



**Fig 1:** Section of liver of control group showed normal hepatocytes, normal central vein, and normal arrangement of liver plate (40X)

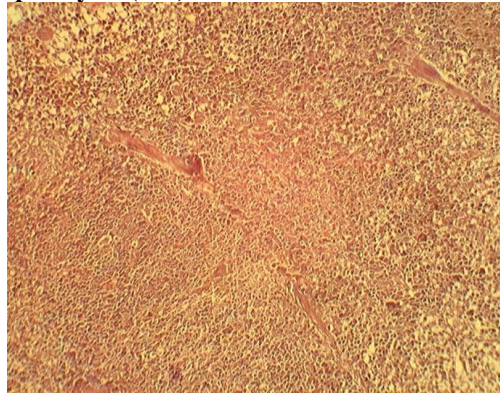


**Fig 2:** Histopathological section of liver of mice treated with 50mg/kg body weight showed: Congestion with dilation of portal vein (CP), Dilation of sinusoids (DS). Mononuclear cell aggregation (M).

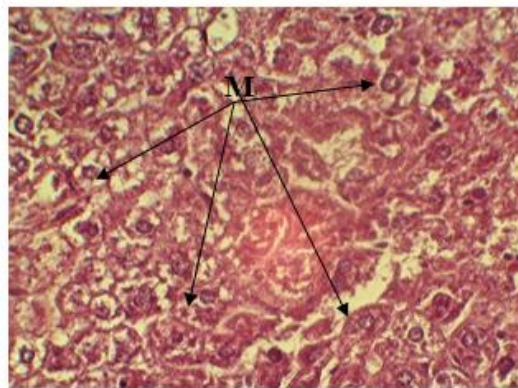


**Fig. 3:** Histopathological section of liver of mice treated with 100 mg / kg body weight showed: small granulomatous lesion of mononuclear cells (M), Enlargement and proliferation of kupper cells (EK),

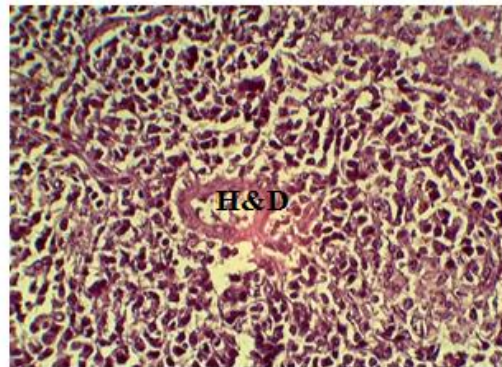
Severe necrosis (N). Severe vacuolar degeneration of hepatocytes (DH).



**Fig 4:** Section of spleen of control group showed normal white pulp and normal red pulp (40X).

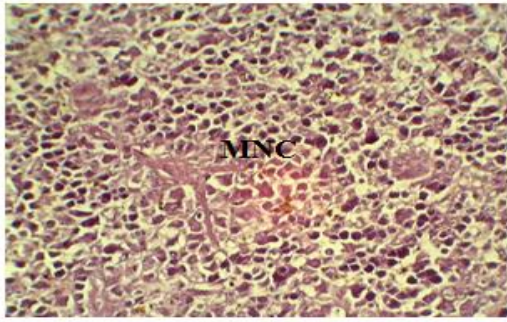


**Fig 5:** Histopathological section of spleen of mice treated with 50mg/kg body weight showed: Infiltration of megakaryocyte

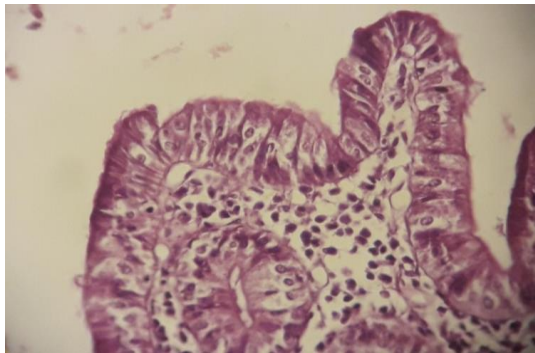


**Fig 6:** Histopathological section of spleen of mice treated with 100 mg/kg body weight showed hypertrophy of central arteriole with dilation.

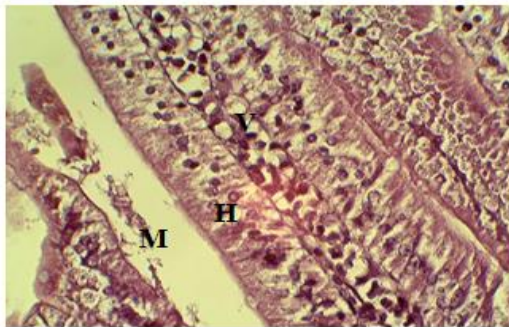



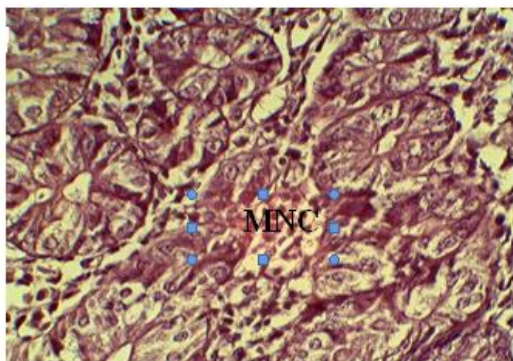
**Fig 7: Histopathological section of spleen of mice treated with 100 mg / kg body weight showed: red pulp infiltration of mononuclear cell (MNC) mainly macrophage and plasma cell.**



**Fig 8: Section of intestine for control group showed normal histology (40X).**



**Fig 9: Histopathological section of intestine of mice treated with 50 mg / kg body weight showed vacuolar degeneration of epithelial cell (V) with hyperplasia of goblet cell (H) which produce allots of mucin(M).**



**Fig 10: Histopathological section of intestine of mice treated with 100mg/kg body weight showed: infiltration of inflammatory cells between glands (MNC).**

## REFERENCES

- Bancroft, J. and A. Stevens, Theory and practice of histological technique. 2nd<sup>ed</sup>. Churchill Livingstone, London Pp. 662 (1982).
- Bjarnason, I., Zanelli, G. and P. Prouse, Blood and protein loss via small-intestinal inflammation induced by nonsteroidal anti-inflammatory drugs. *Lancet* Pp. 711–714 (1987).
- Casey, T.P., Azathioprine (Imuran) administration and the development of malignant lymphomas in NZB mice. *Clinical and Experimental Immunology* 3: 305 (1968).
- César, M., María, D. and M. Fernández, Azathioprine Acts upon Rat Hepatocyte Mitochondria and Stress-Activated Protein Kinases Leading to Necrosis: Protective Role of NAcetyl-L-cysteine. *Journal of Pharmacology and Experimental Therapeutics* 104: 269-86 (2004).
- Day, R.O., Furst, D., E., Van riel, L. and B. Bresnihan, Antirheumatic therapy: Actions and outcomes, USA. Springer science + Business Media Pp. 4-5 (2005).
- Dearden, M.J.C. and R.M. Nicholson, Correlation between gastric intancy and anti-inflammatory activity of non-steroidal anti-inflammatory drugs. *J. Pharin. Pharinacol.* 36: 713-715 (1984).
- Evans W.E., Pharmacogenetics of thiopurine S-methyltransferase and thiopurine therapy. *Ther. Drug Monit.* 26(2): 186–1891 (2004).
- Gately, S. and W. Li, Multiple roles of COX-2 in tumor angiogenesis: a target for antiangiogenic therapy. *Semin. Oncol.* 31: 2–11 (2004).
- Gearry, R.B.1. and M.L. Barclay, Azathioprine and 6-mercaptopurine pharmacogenetics and metabolite monitoring in inflammatory bowel disease. *J. Gastroenterol. Hepatol.* 20(8): 1149 - 57 (2005).
- Hascheck, W.M. and Rausseaux, Fundamentals of Toxicologic Pathology. Academic Press, San Diego (1998).
- Jewell, D.P. and S.C. Truelove, Azathioprine in Ulcerative Colitis: An Interim Report on a Controlled Therapeutic Trial. *British Medical Journal* 1: 709-712 (1972).
- Machalinska, A., Nowak, Jarema, A., Wiszniewska and B. Machalinski, In vivo effects of sodium fluoride on bone marrow transplantation in lethally irradiated mice. *Floride* 35(2): 81 – 89 (2002).
- Maltzman, J.S. and G.A. Koretzky, Azathioprine: Old drug, new action. *Journal of Clinical Investigation* 111(8): 1122–1124 (2003).
- Mion, F.B., Napoleon, F. Berger, M. Chevallier, S. Bonvoisin and L. Descos, Azathioprine induced liver disease: nodular regenerative

- hyperplasia of the liver and perivenous fibrosis in a patient treated for multiple sclerosis. *Gut*. 32: 715-717 (1991).
- Niels, T., Wolfgang M., Bernd B., Burkhard B., Jürgen B., Stephan M., Dietrich H., Christian M., Tobias K., Wolfgang K., Britta S., Ulf H., Joseph W., Attyla D. and S. Andreas, Azathioprine-induced Acute Pancreatitis in Patients with Inflammatory Bowel Diseases—A Prospective Study on Incidence and Severity. *J. Crohns. Colitis*. 10(1): 61–68 (2016).
- Patel, A.A., Swerlick, R.A. and C.O. McCall, Azathioprine in dermatology: The past, the present and the future. *Journal of the American Academy of Dermatology* 55(3): 369–389 (2006).
- Pytrus, T.1., Flis A., Iwańczak F. and B. Iwańczak, The frequency of anemia in children with newly diagnosed Crohn's disease in children. *Pol. Merkur. Lekarski*. 34(203): 263-268 (2013)
- Sami Naveed, *Autoimmune Bullous Diseases: Approach and Management*, Springer Pp. 83 (2016).
- Schmaier A.H., Laboratory evaluation of hemostatic and thrombotic disorders. In: Hoffman R., Benz E.J. Jr, Shattil S.J. Hoffman, *Hematology: Basic Principles and Practice*. 5th Edi., Philadelphia, Elsevier Pp. 122 (2008).
- Siddique, T., Rabbi A.F., Najam, S.S., Khan, A., Qureshi, J.A., Khurshid, M., Islam, M. and M. Zain, Amplification, cloning and expression of the reg3  $\delta$  gene from mouse pancreas. *Pak. J. Biotechnol.* 12(1): 55-61 (2015).
- Steinhilber, D., Schubert-Zsilavecz, M. and H.J. Roth, *Medizinische Chemie* (in German). Stuttgart: Deutscher Apotheker Verlag Pp. 340 (2005).
- Weersma, R.K., Peters, F.T.M., Oostenbrug, L.E., van den Berg, A.P., van Haastert, M., Ploeg, R.J., Posthumus, M.D., Homan van der Heide, J.J., Jansen, P.L.M. and H.M. van Dullemen, Increased incidence of azathioprine-induced pancreatitis in Crohn's disease compared with other diseases. *Alimentary Pharmacology & Therapeutics* 20(8): 843–850 (2004).